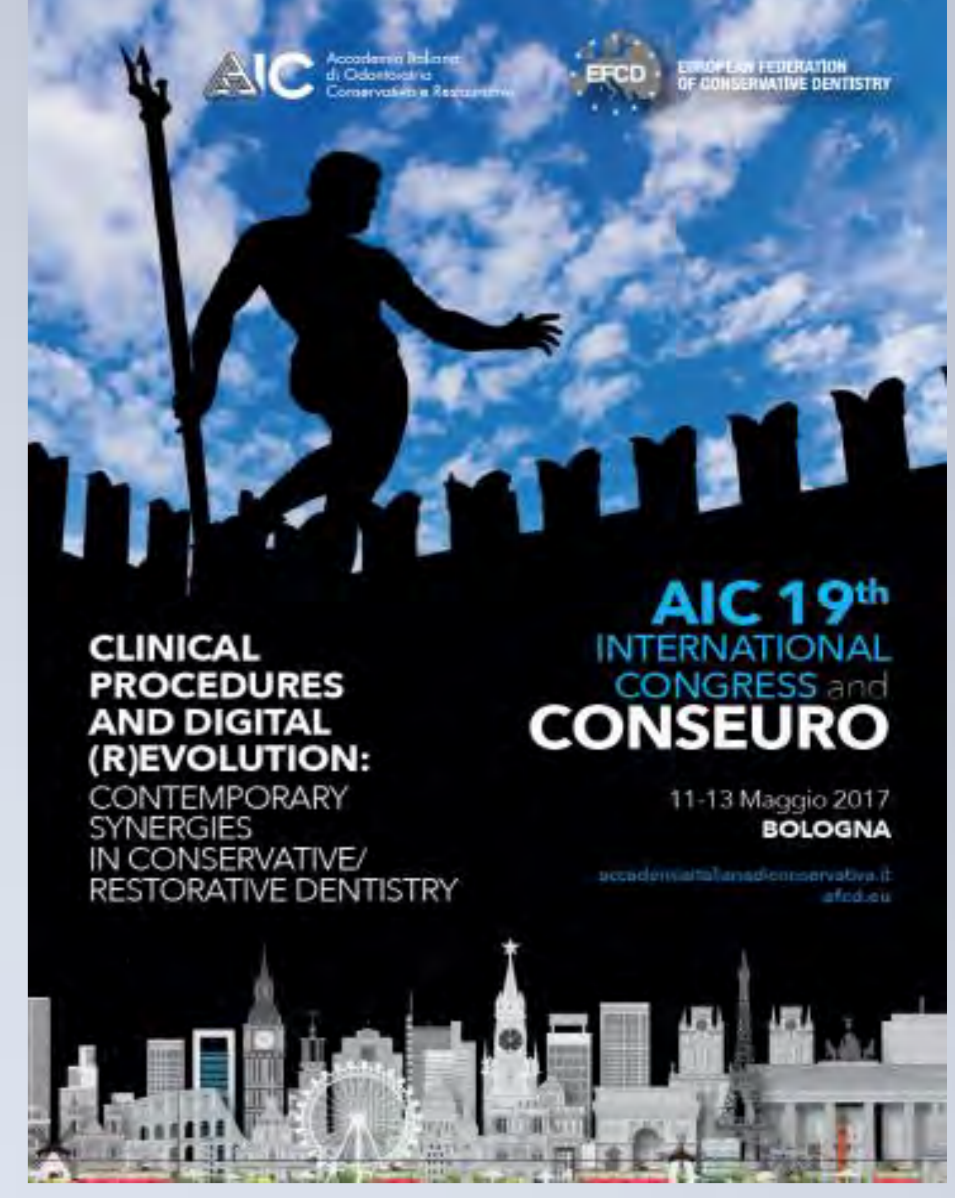




Conservative treatment of aesthetic problems in elderly patient with high expectations

Veselinova Maya, Paximada Chariklia

National and Kapodistrian University of Athens, Dental School,
Department of Operative Dentistry, Athens, Greece



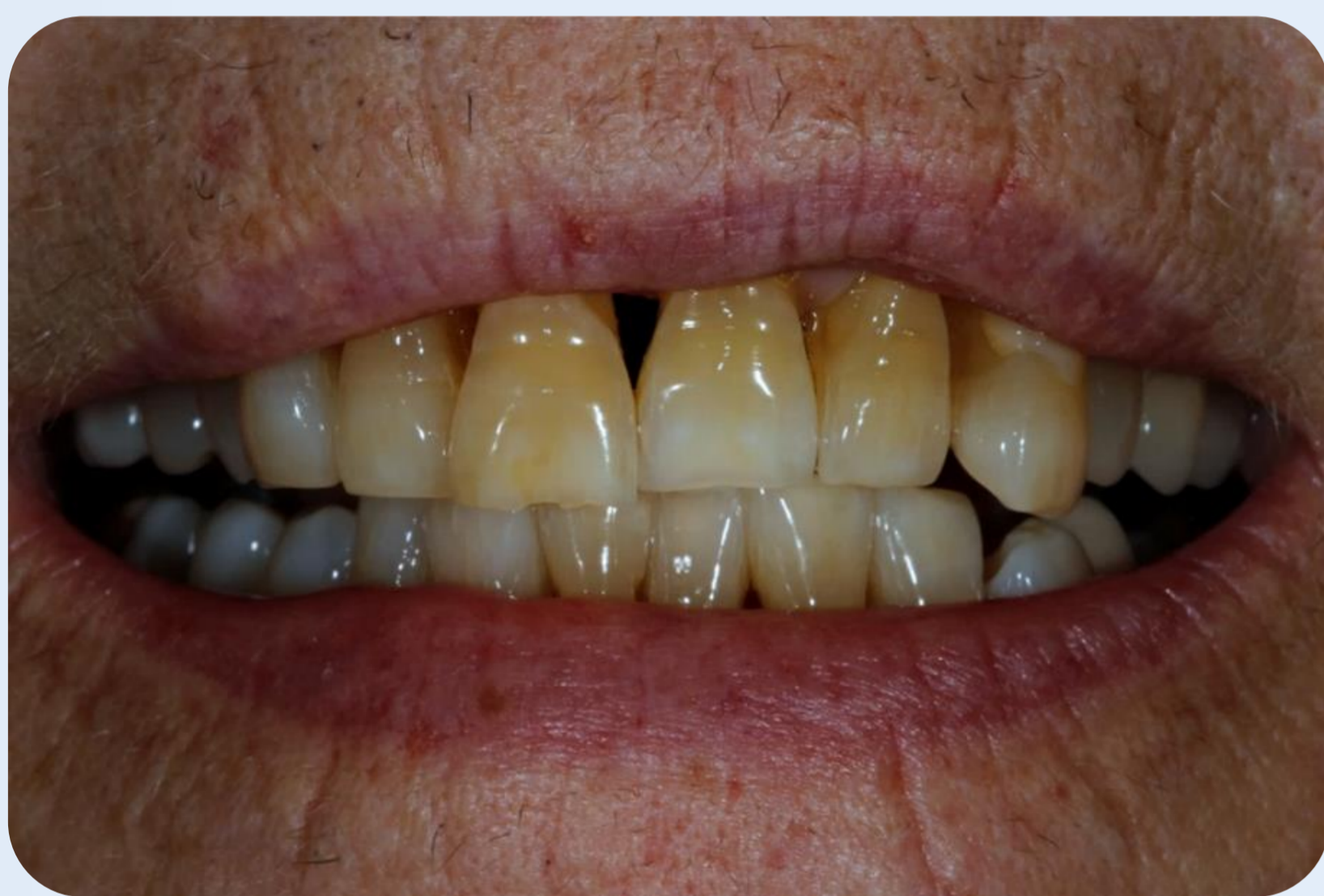
Objective: The purpose of this clinical case is the presentation of possibilities of minimal intervention dentistry to achieve an aesthetic result in an elderly patient.

Materials and Methods: A 74-year-old female patient in good medical condition was referred for dental treatment to our department as she was not satisfied with her smile. Clinical examination revealed extensive non-carious cervical lesions, incisal wear, black interdental triangles, old composite resin restorations with poor marginal quality and tooth migration due to periodontal disease. Her requirements were whiter teeth and improvement of her smile with minimal intervention and low cost. A combination of conservative methods was selected. Teeth were bleached using carbamide peroxide 16% for two weeks. Then we proceeded to restore cervical lesions with simultaneous treatment of the other aesthetic problems. All restorations were done freehand with enamel and dentin composite resin shades.

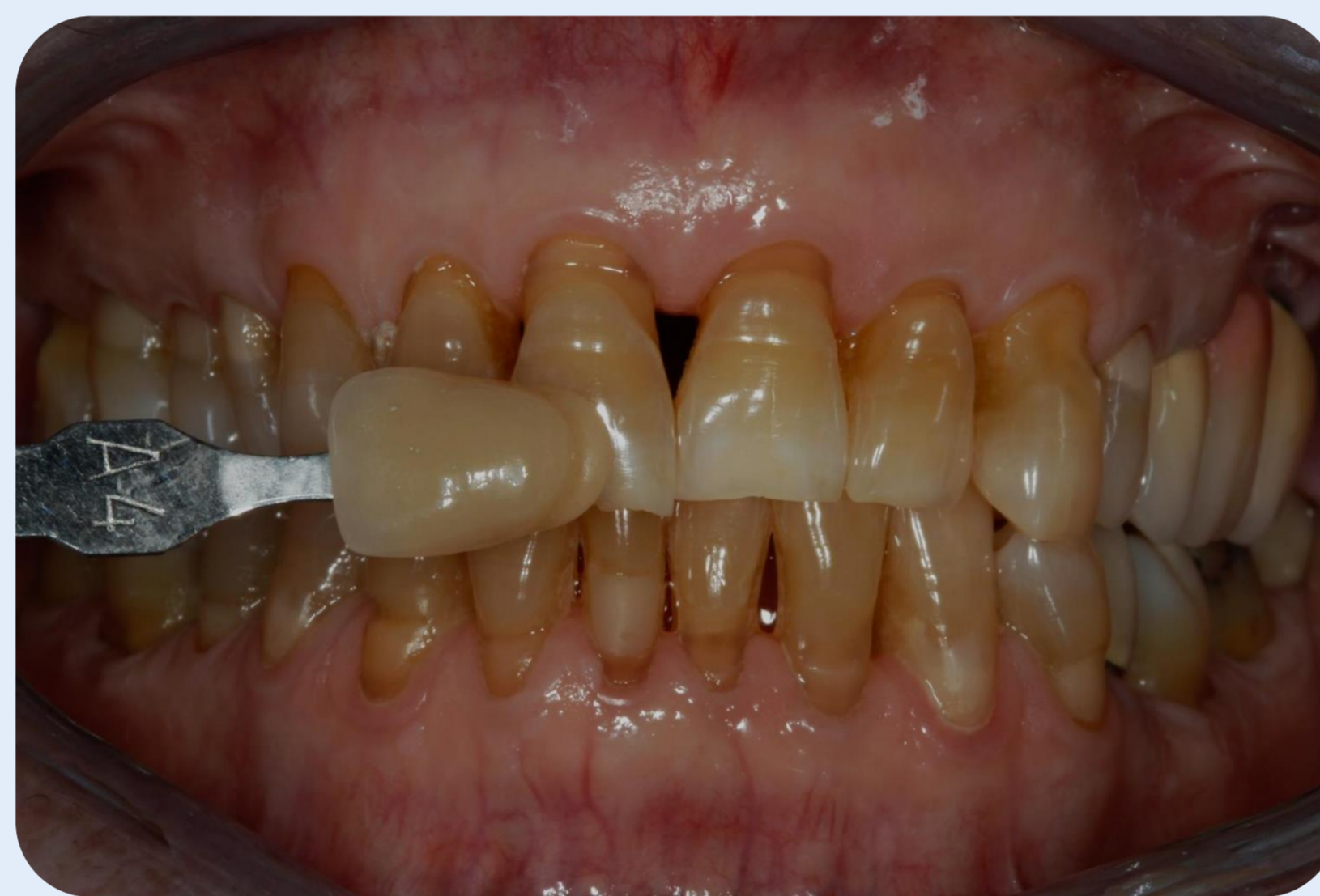Results: The patient was fully satisfied with the result and after 1 year the restored teeth present excellent clinical appearance.

Conclusion: Conservative treatment of these defects is important not only to restore function and aesthetics, but also presents a positive psychological impact on elderly patients.

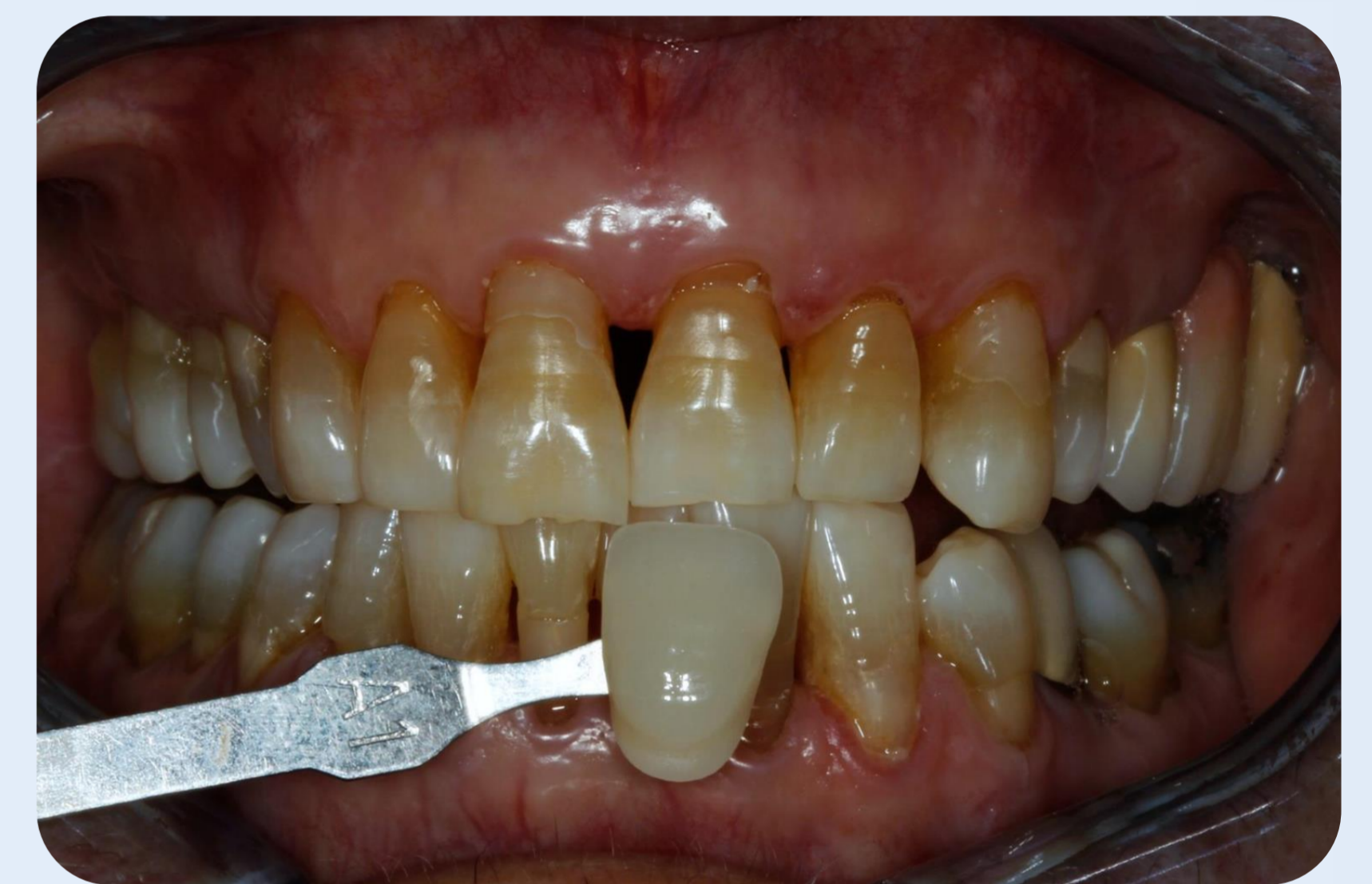Clinical Case



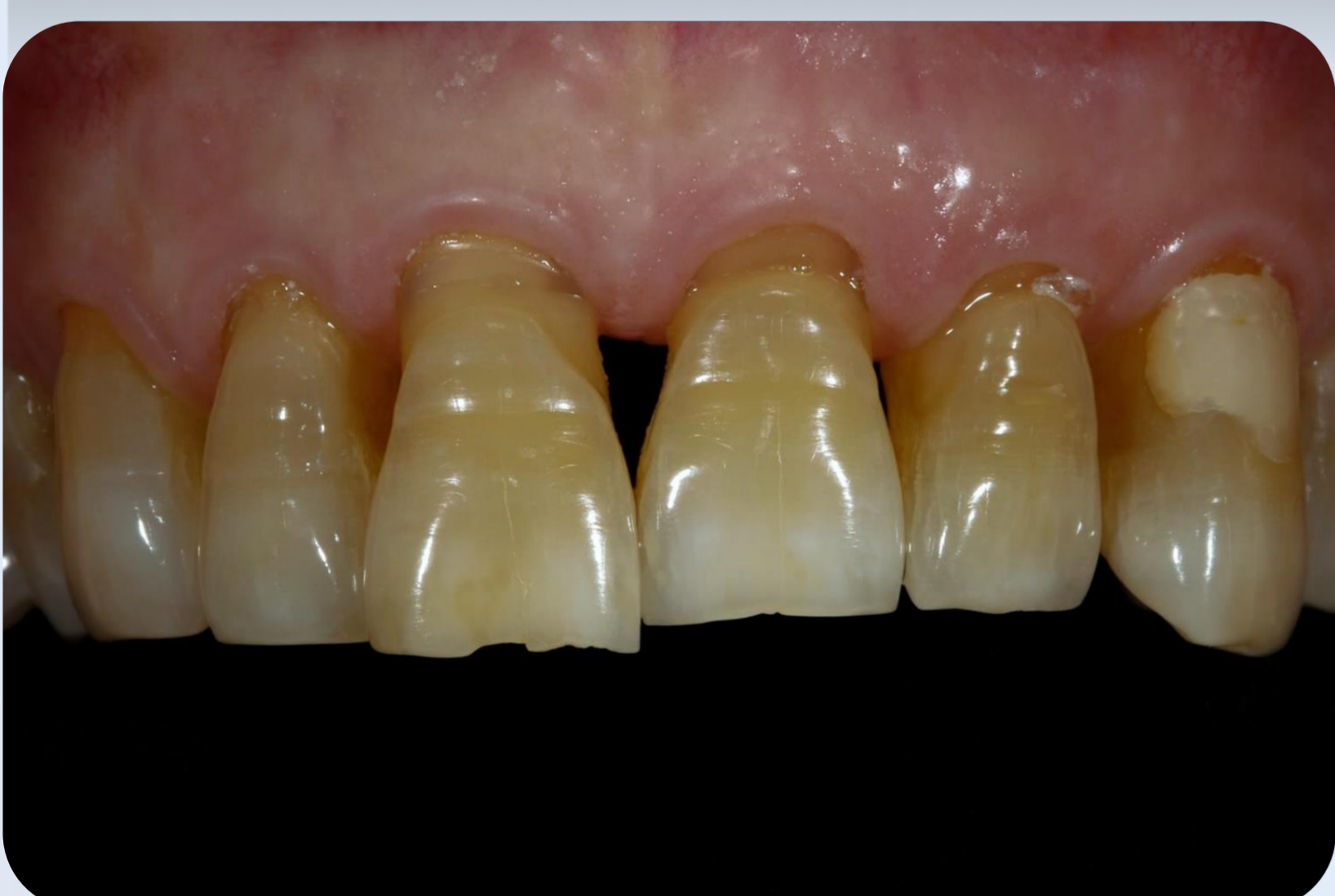1. Patient's smile



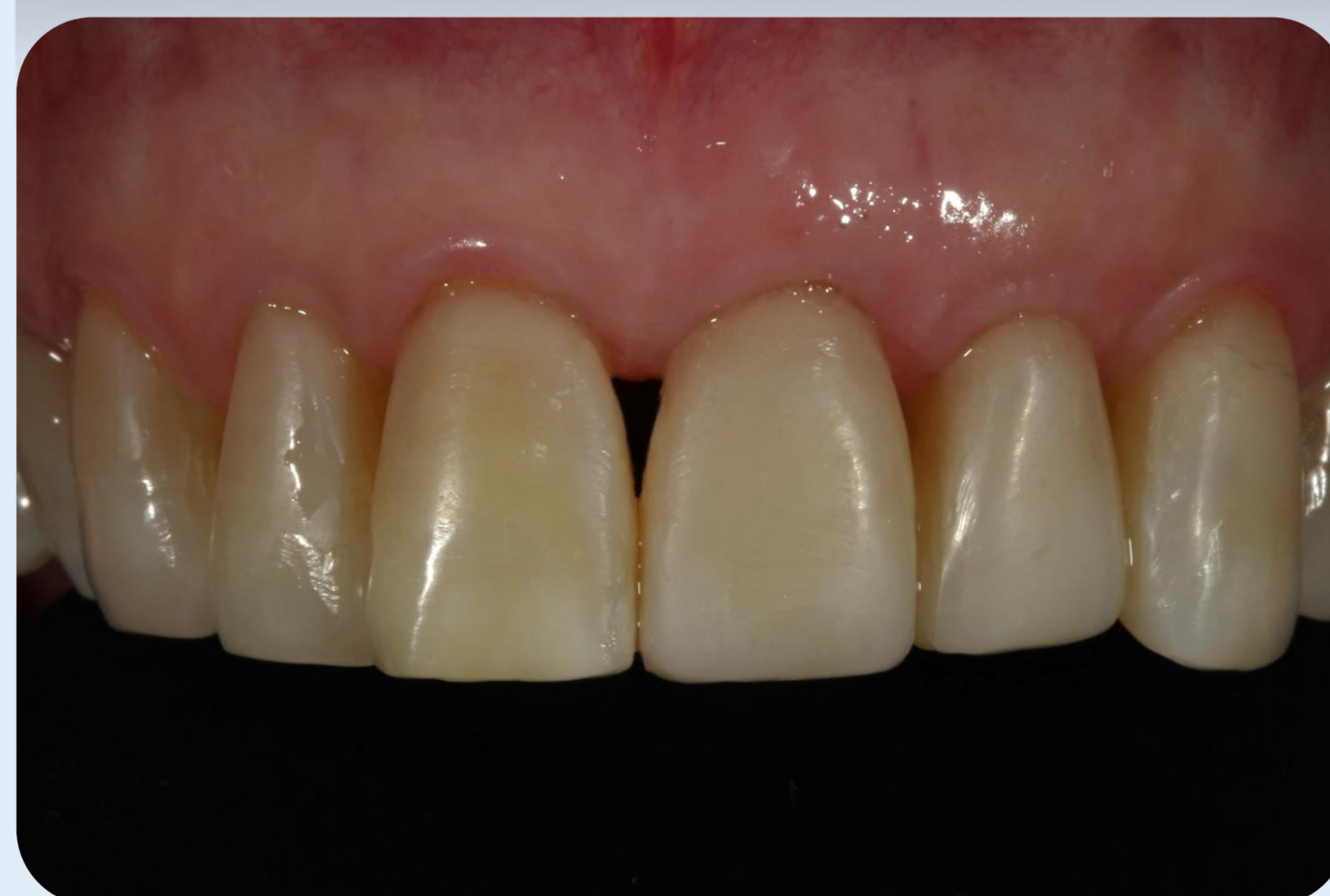2. Initial color A4



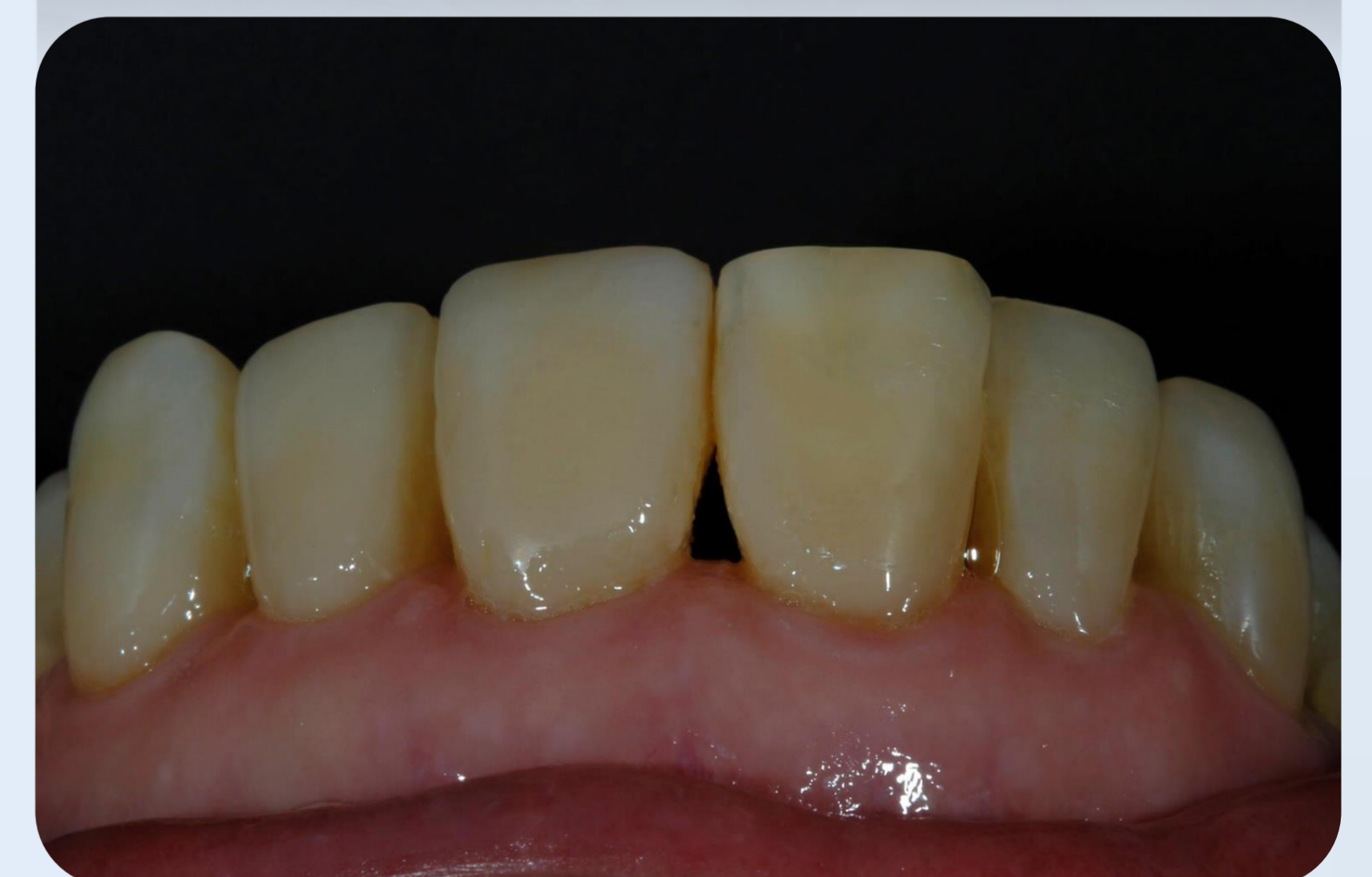3. Final color of the incisal part A1



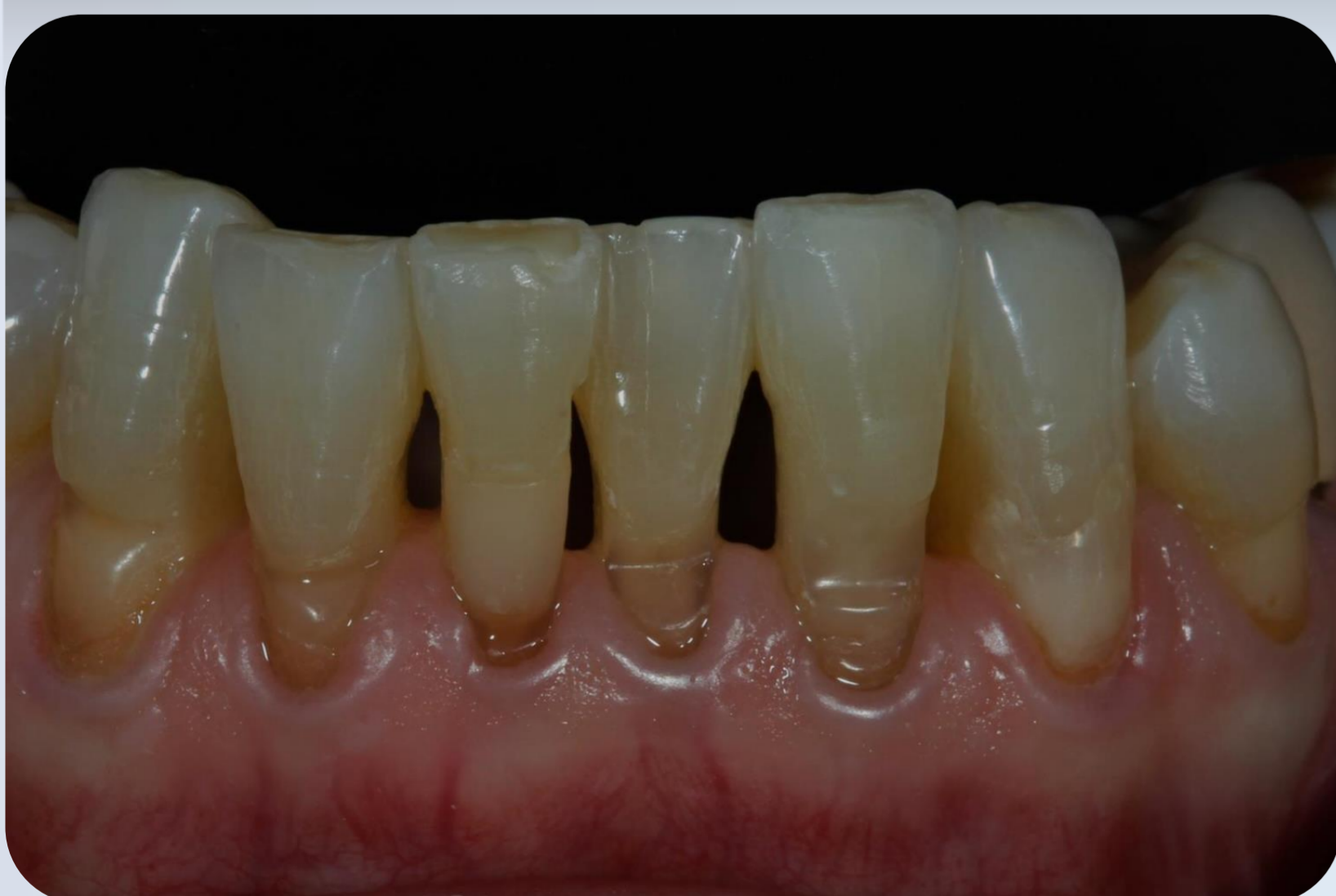4. Upper 6 front teeth



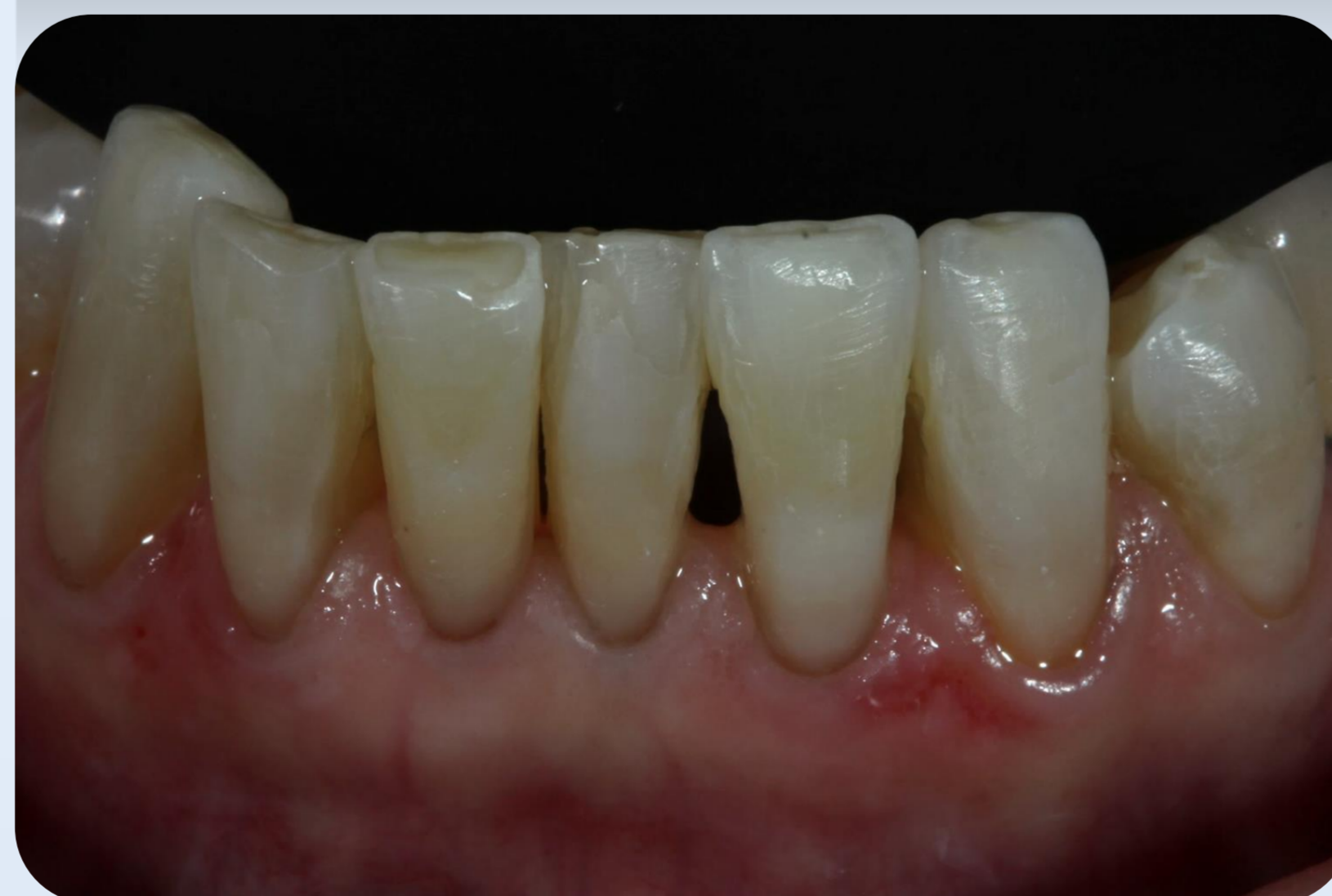5. Freehand composite resin restorations



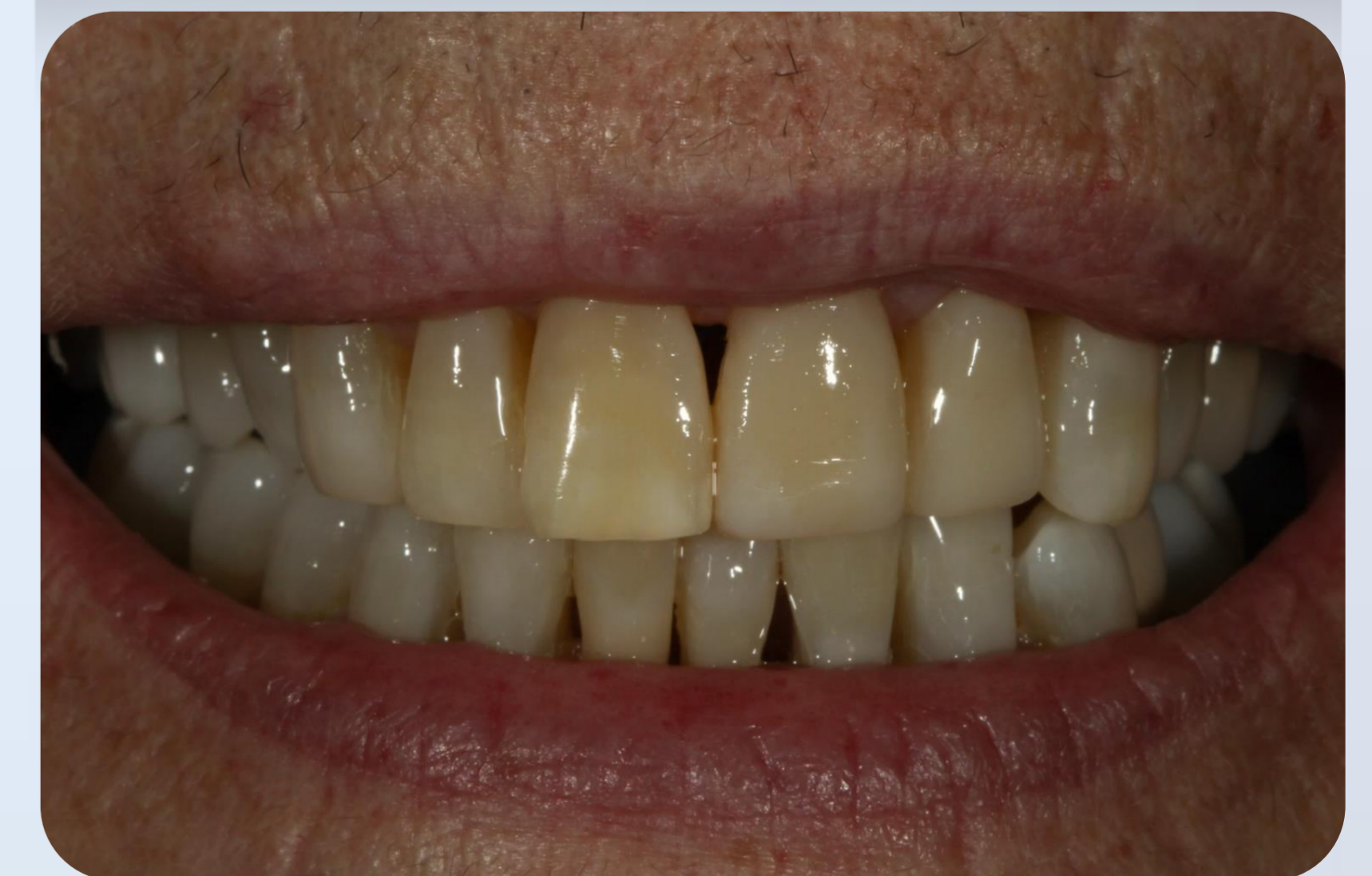6. From different angle



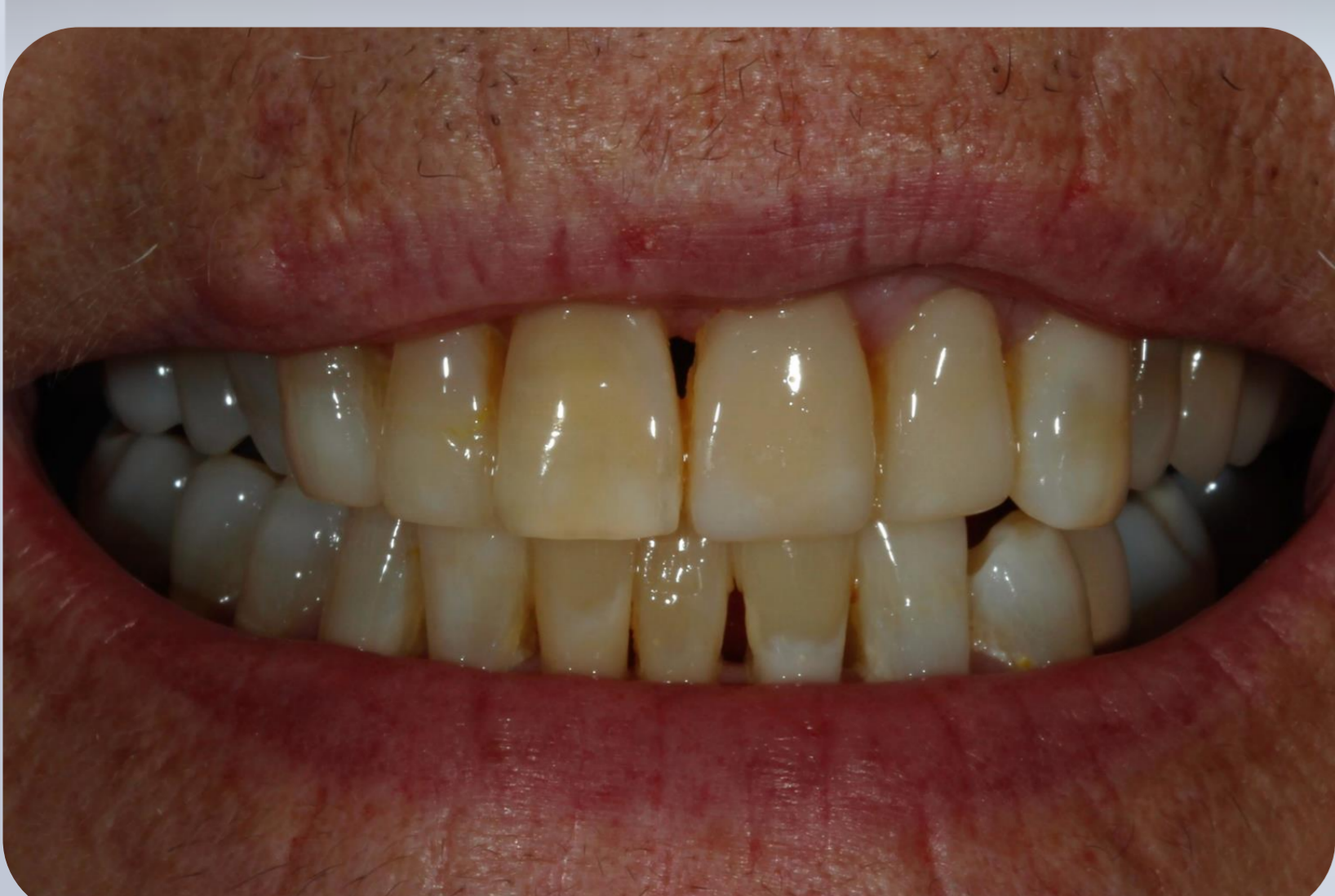7. Lower 6 front teeth



8. Freehand composite resin restorations



9. Patient's final smile



10. After 1 year

References

1. Epstein S, Corvin SS. *Special considerations for restorative dentistry in geriatric patients*. Dent Clin North Am. 1985 Apr;29(2):413-9.
2. Nash RW. *Freehand composite veneering--the direct option*. Pract Periodontics Aesthet Dent. 1994 Apr;6(3):89-92, 94.
3. Kelleher MG1, Djemal S, Al-Khayatt AS, Ray-Chaudhuri J, Briggs PF, Porter RW. *Bleaching and bonding for the older patient*. Dent Update. 2011 Jun;38(5):294-6, 298-300, 302-3.